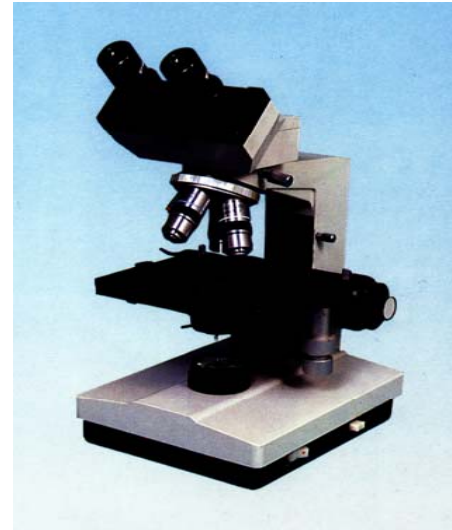
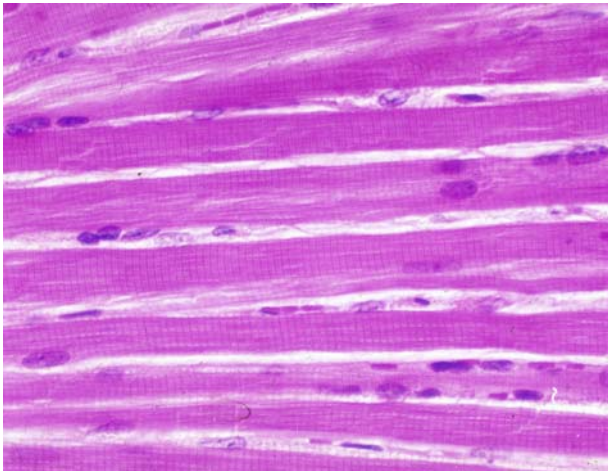



Histology and Embryology



- Chapter 1 Introduction and Cell**
- Chapter 2 Epithelial tissue**
- Chapter 3 Connective Tissue**
- Chapter 4 Blood**
- Chapter 5 Cartilage and Bone**
- Chapter 6 Muscle Tissue**
- Chapter 7 Nerve Tissue**
- Chapter 8 Circulatory System**
- Chapter 9 Immune System**
- Chapter 10 Skin**
- Chapter 11 Digestive Tract**
- Chapter 12 Digestive Gland**
- Chapter 13 Respiratory System**
- Chapter 14 Urinary System**
- Chapter 15 Endocrine System**
- Chapter 16 Sense Organ**
- Chapter 17 Male Reproduction**
- Chapter 18 Female Reproduction**
- Chapter 19 Embryology 1**
- Chapter 20**

Chapter 6 Muscle Tissue

I Slides

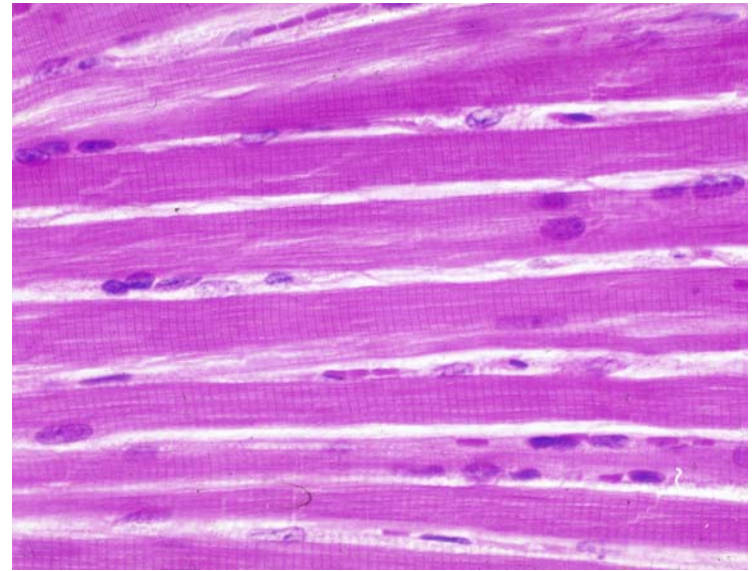
II Sections

NO.11 skeletal muscle

NO.12 cardical muscle

NO.33 cardical muscle

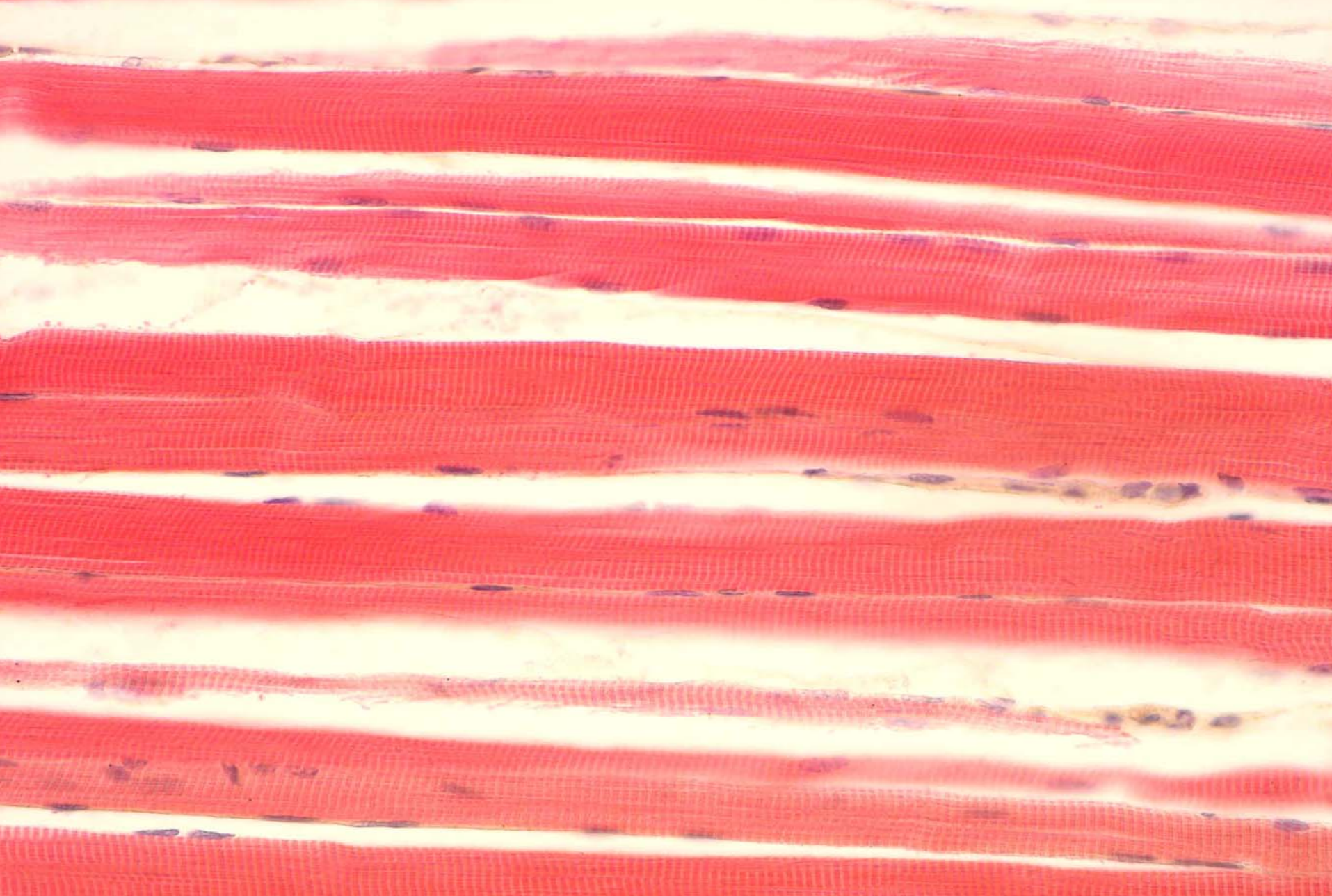
NO.60 smooth muscle



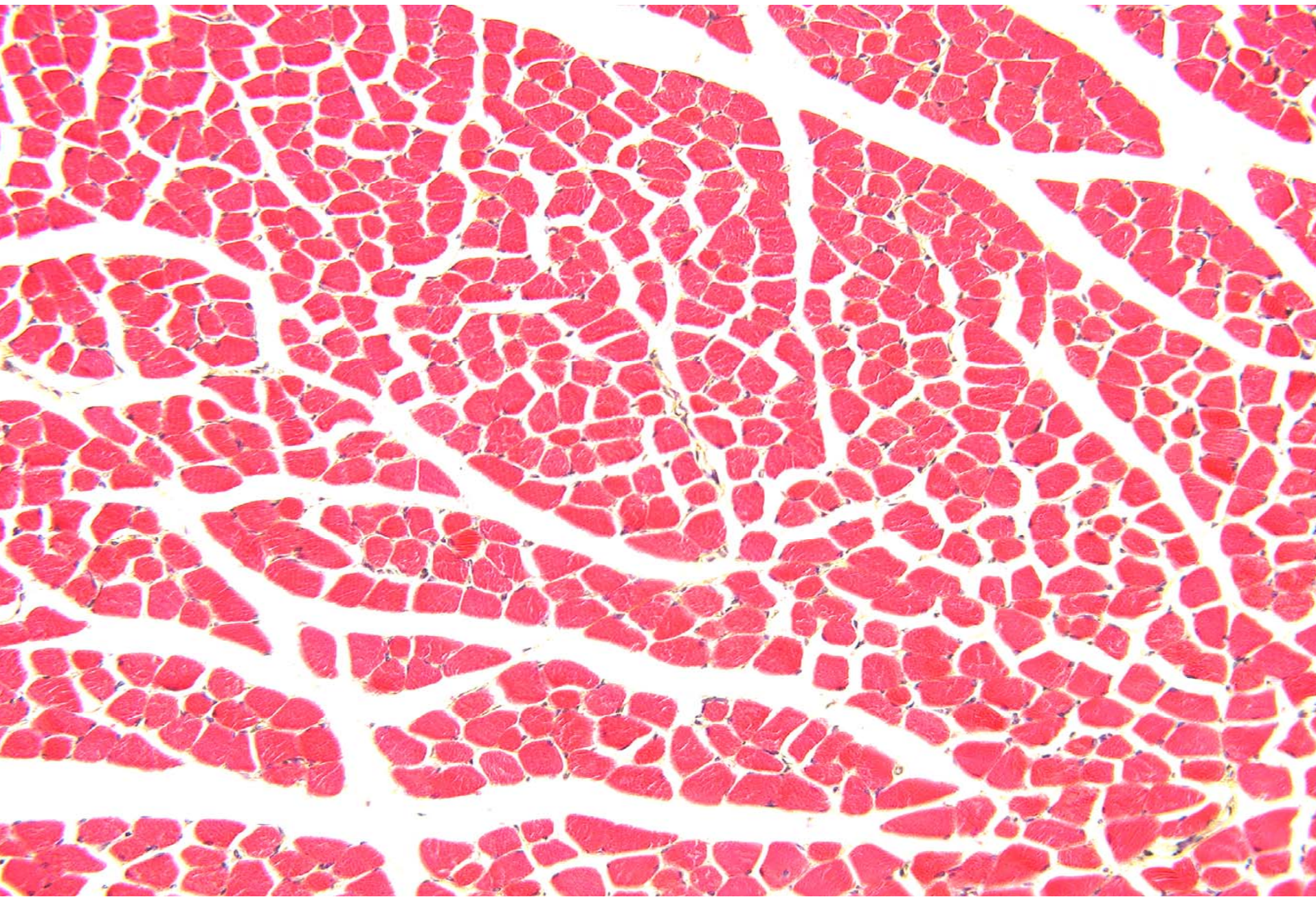
III Drawing: skeletal muscle

IV EM photos:21---24


V Summary



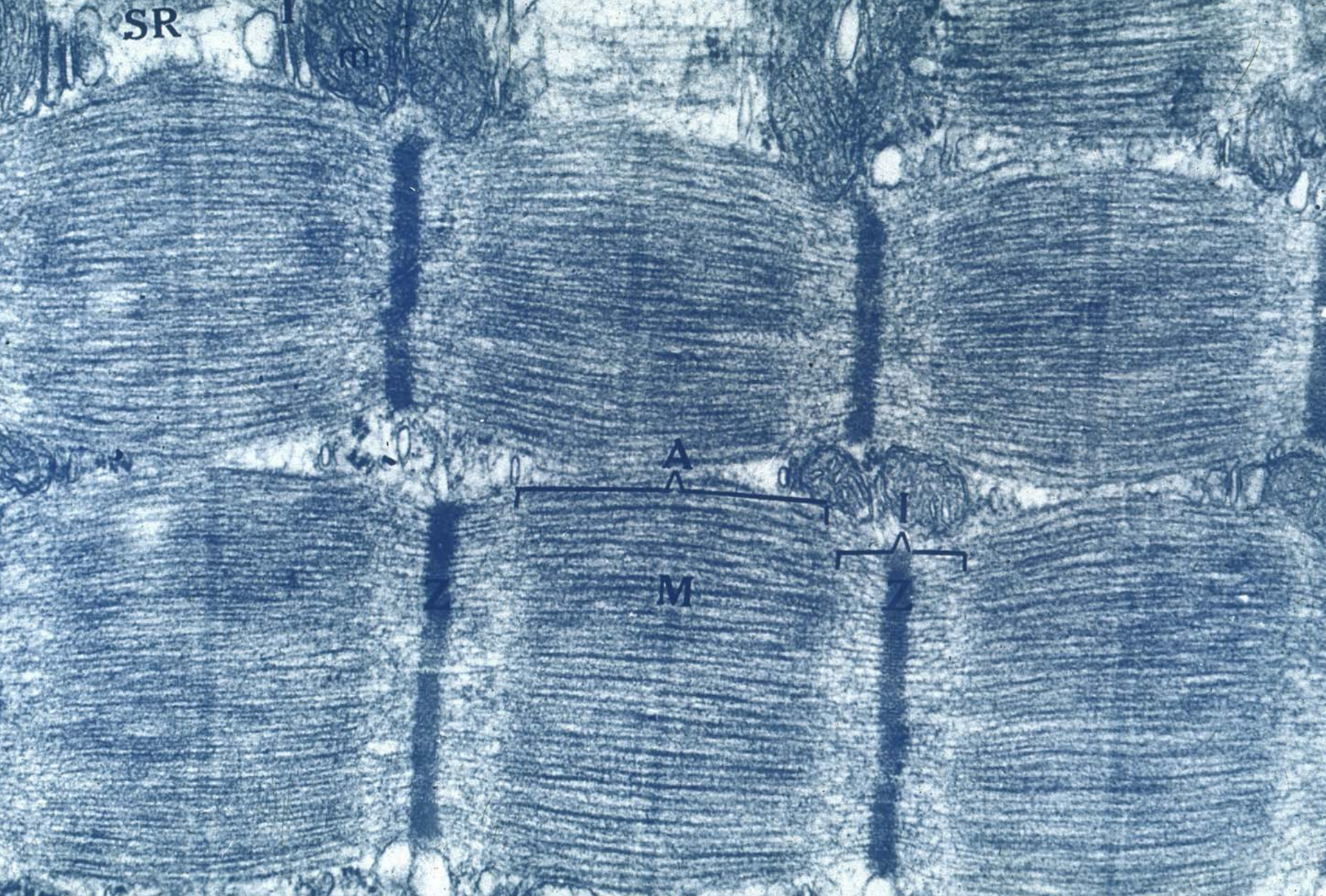
skeletal muscle



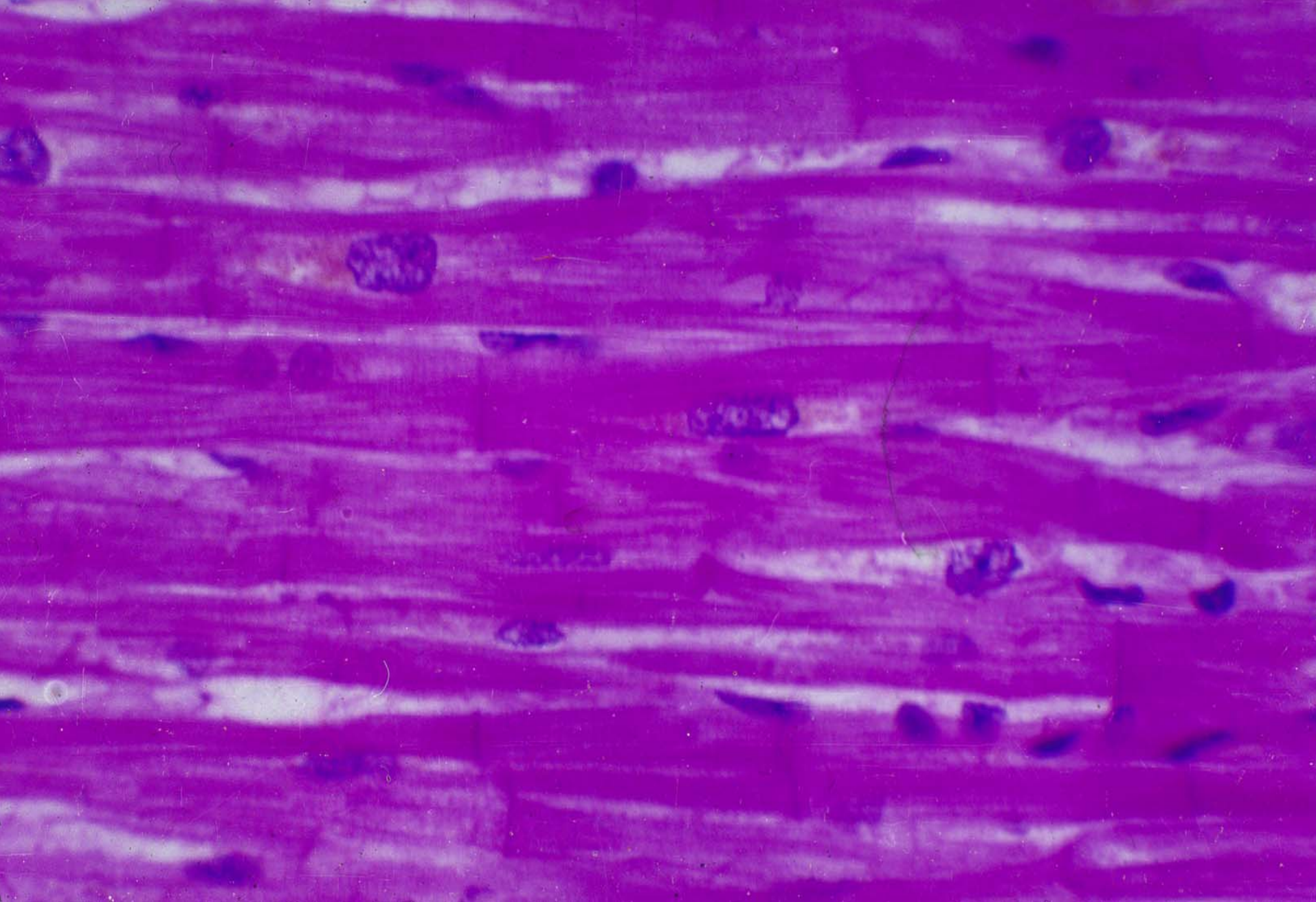
skeletal muscle



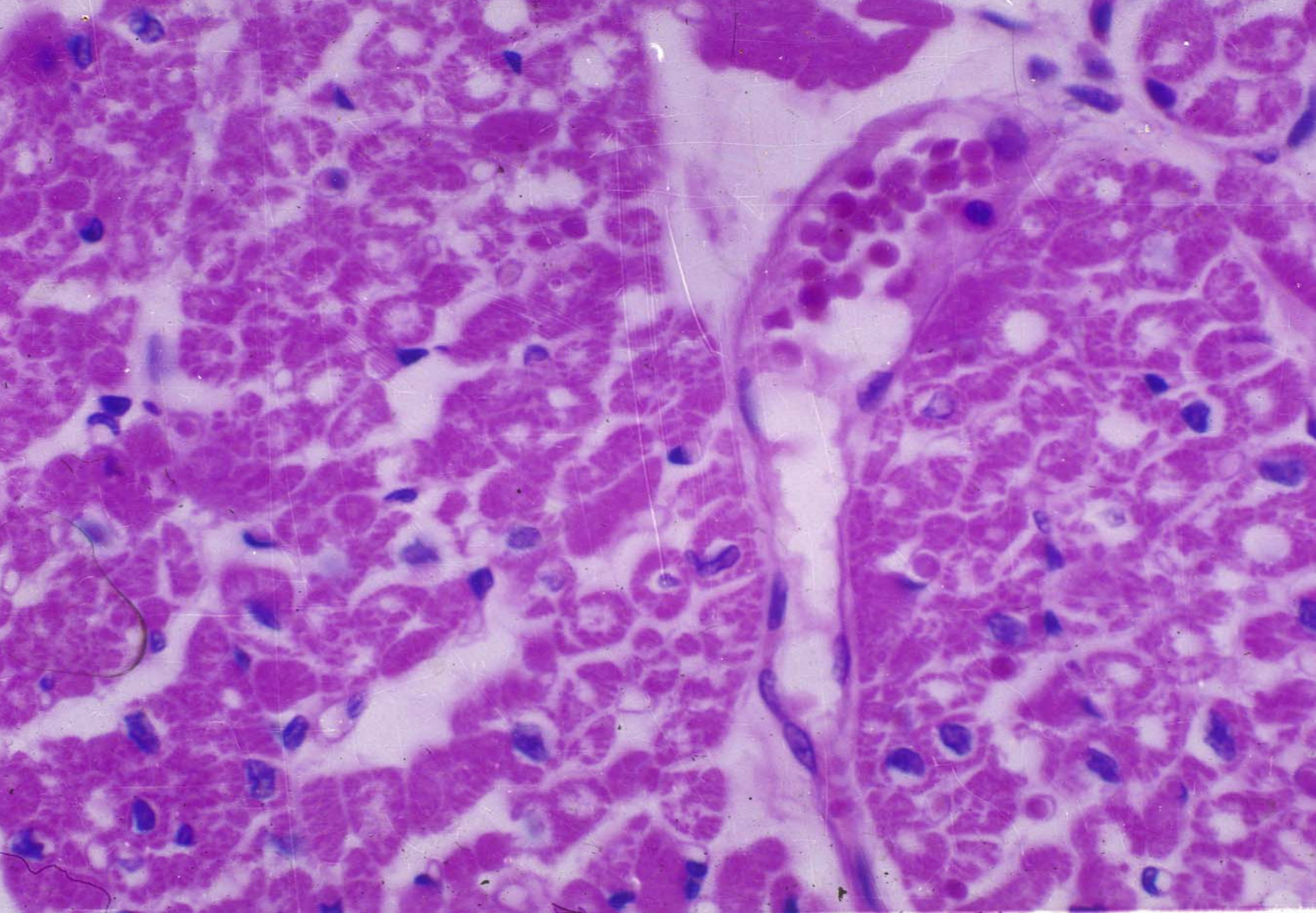
skeletal muscle



skeletal muscle



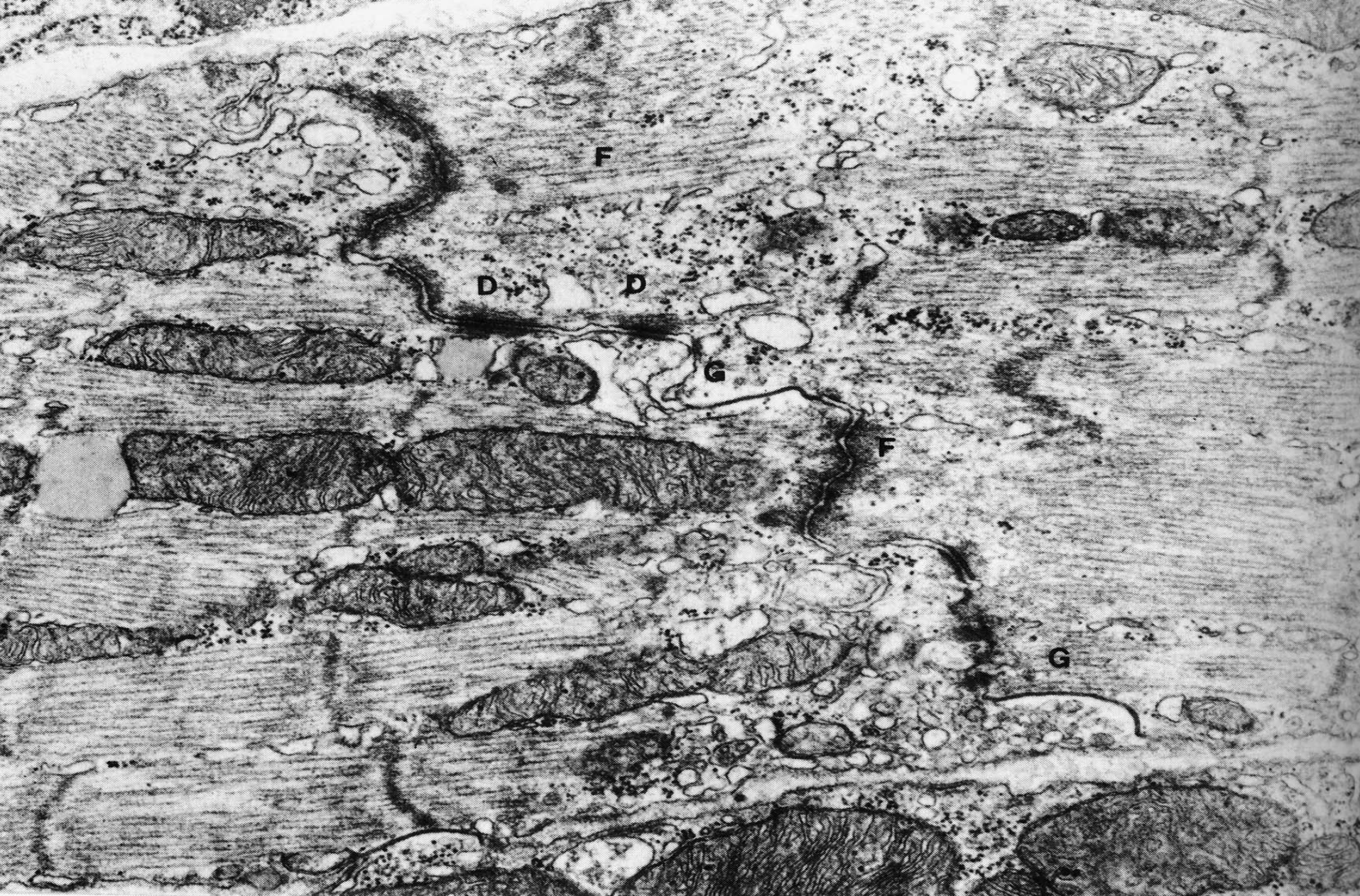
cardiac muscle



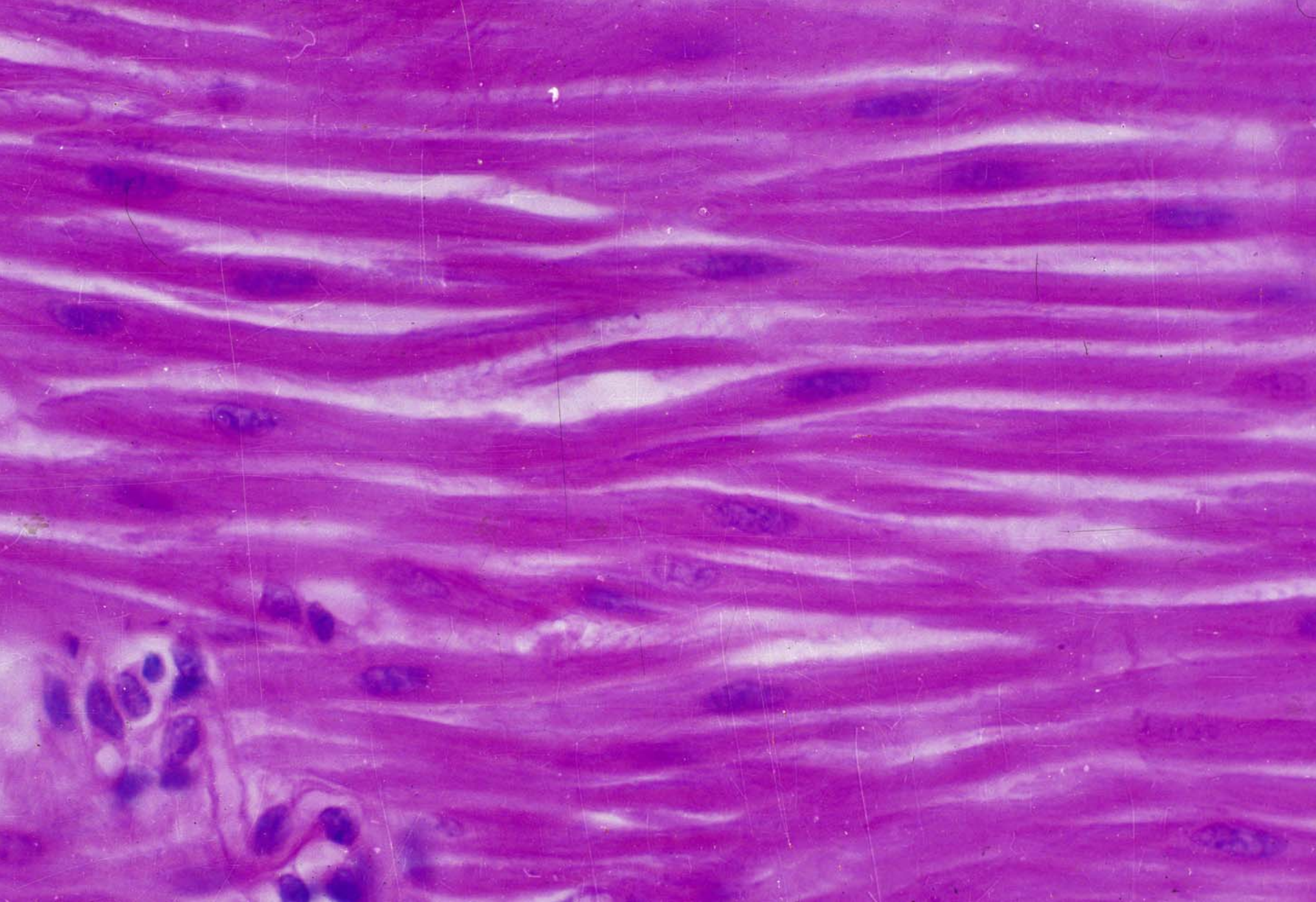
cardiac muscle



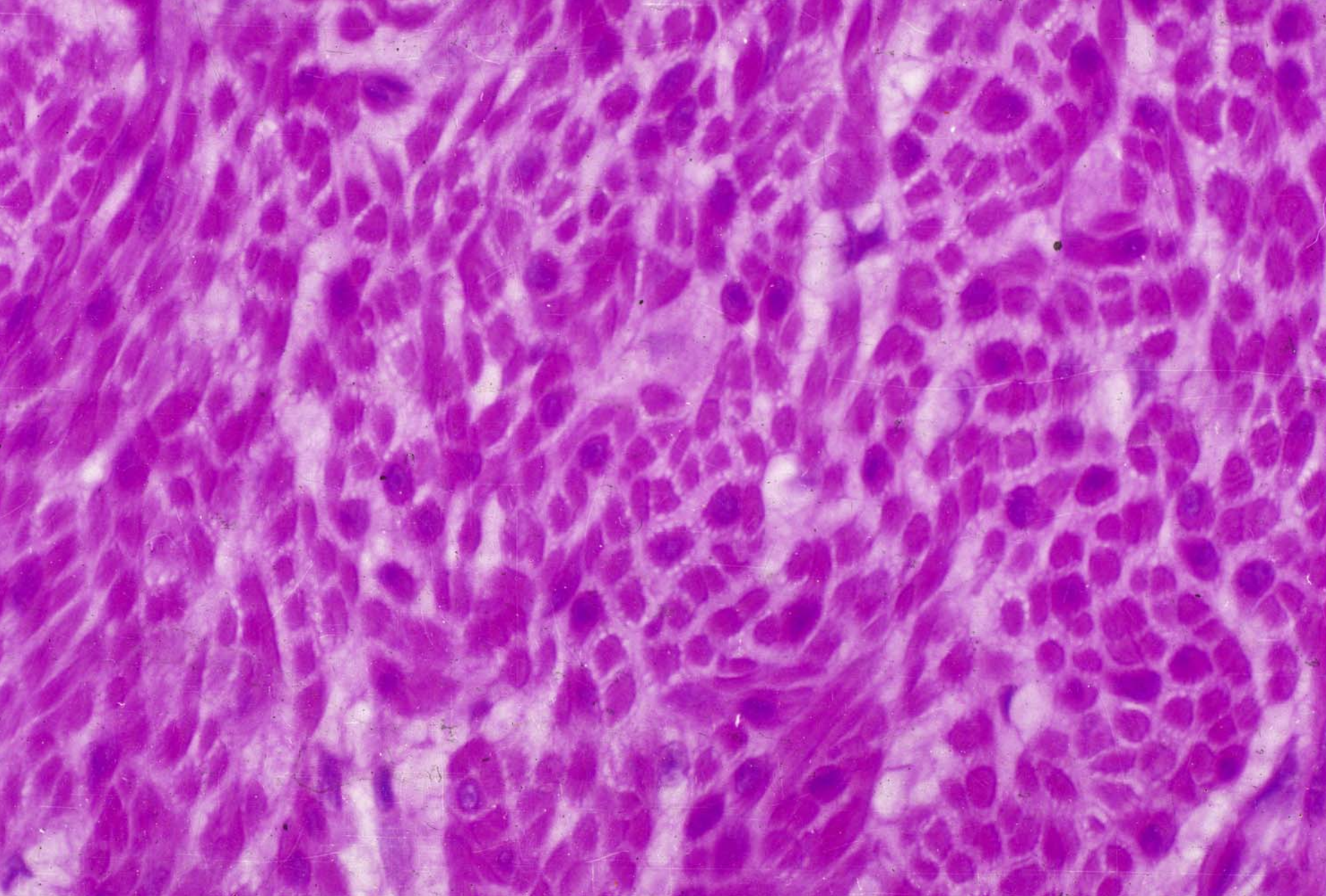
cardiac muscle



intercalated disc



smooth muscle



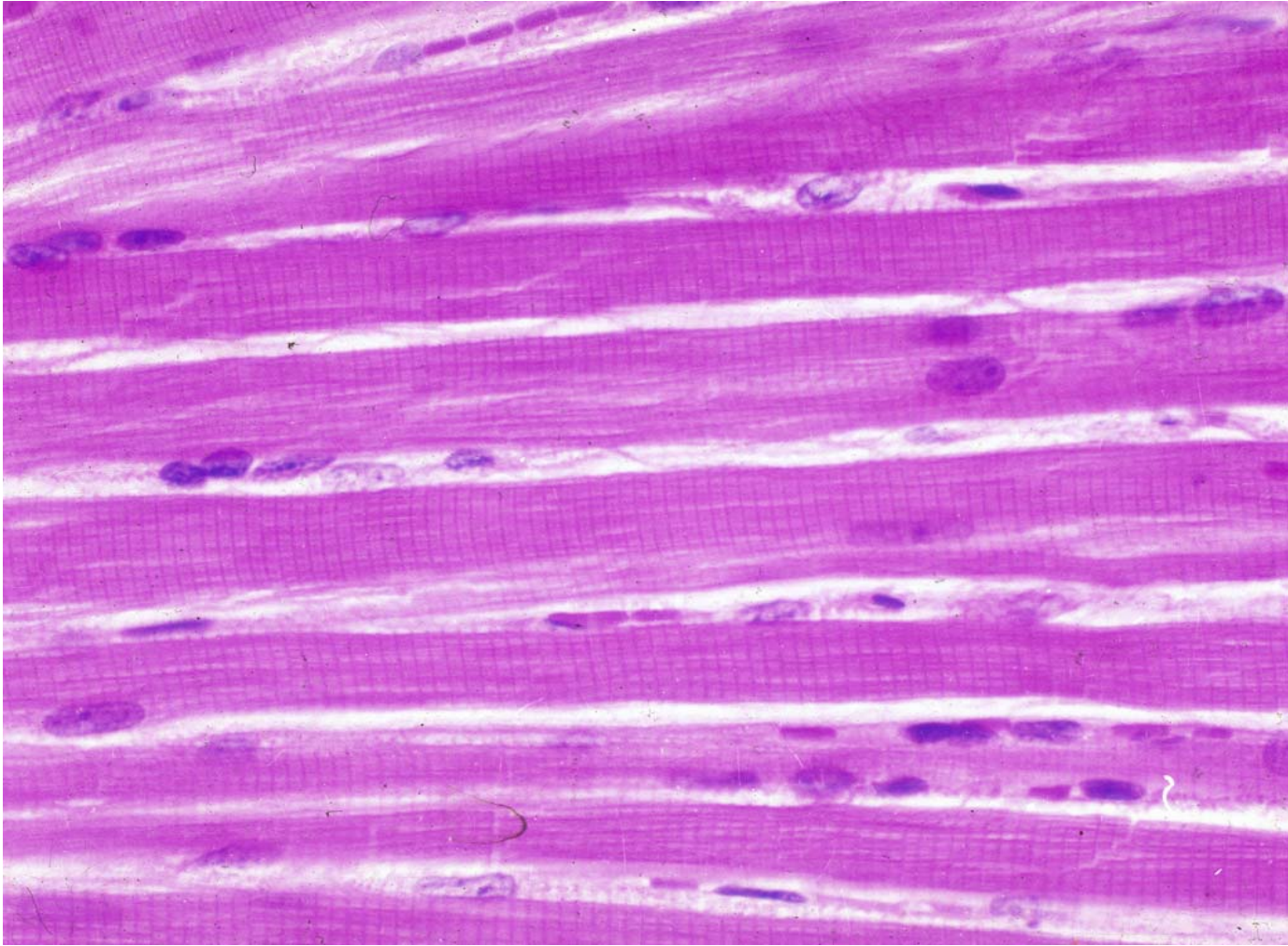
smooth muscle




smooth muscle

Summary

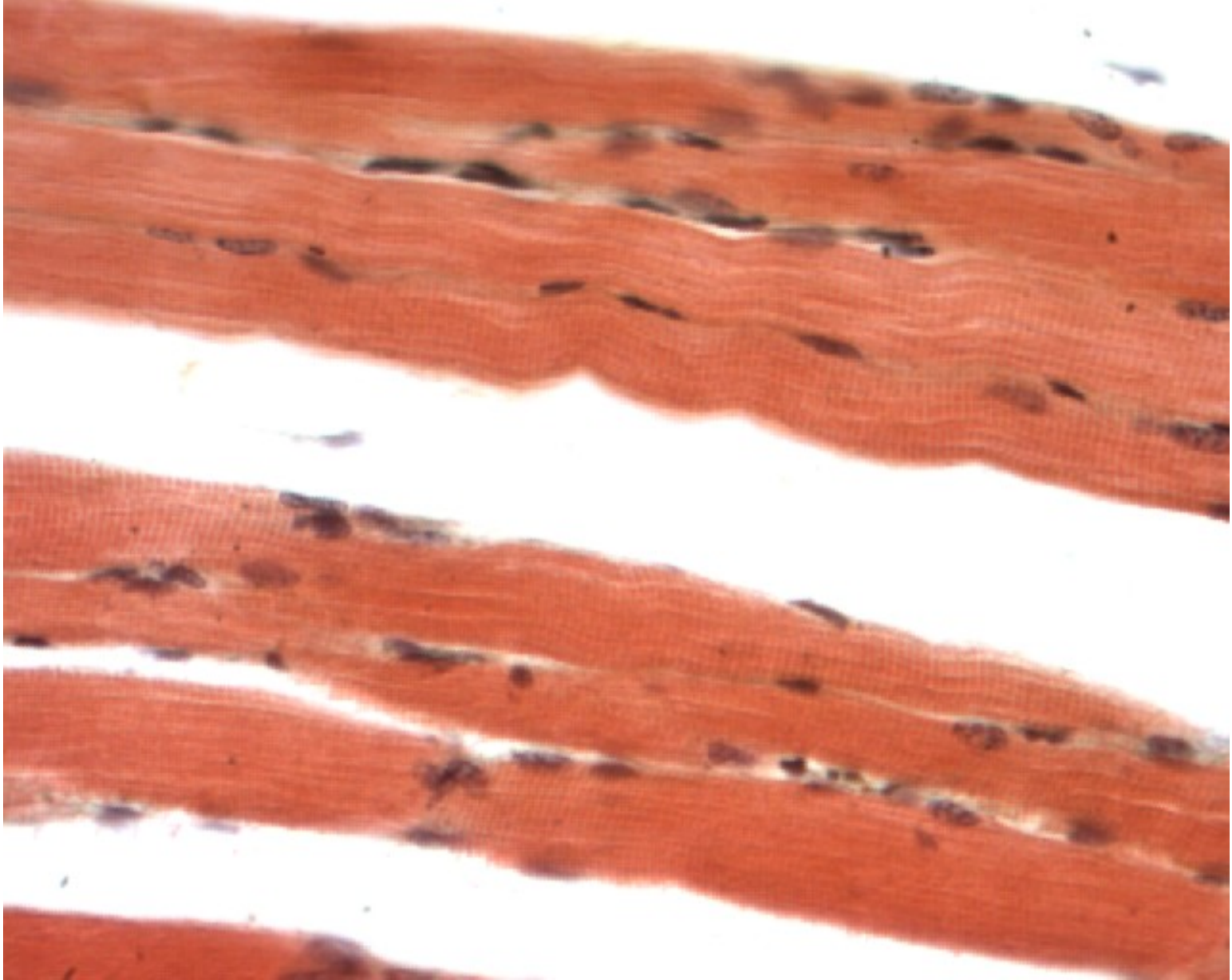
- The type of muscle tissue
- The ultrastructure of skeletal muscle
- The ultrastructure of cardiac muscle



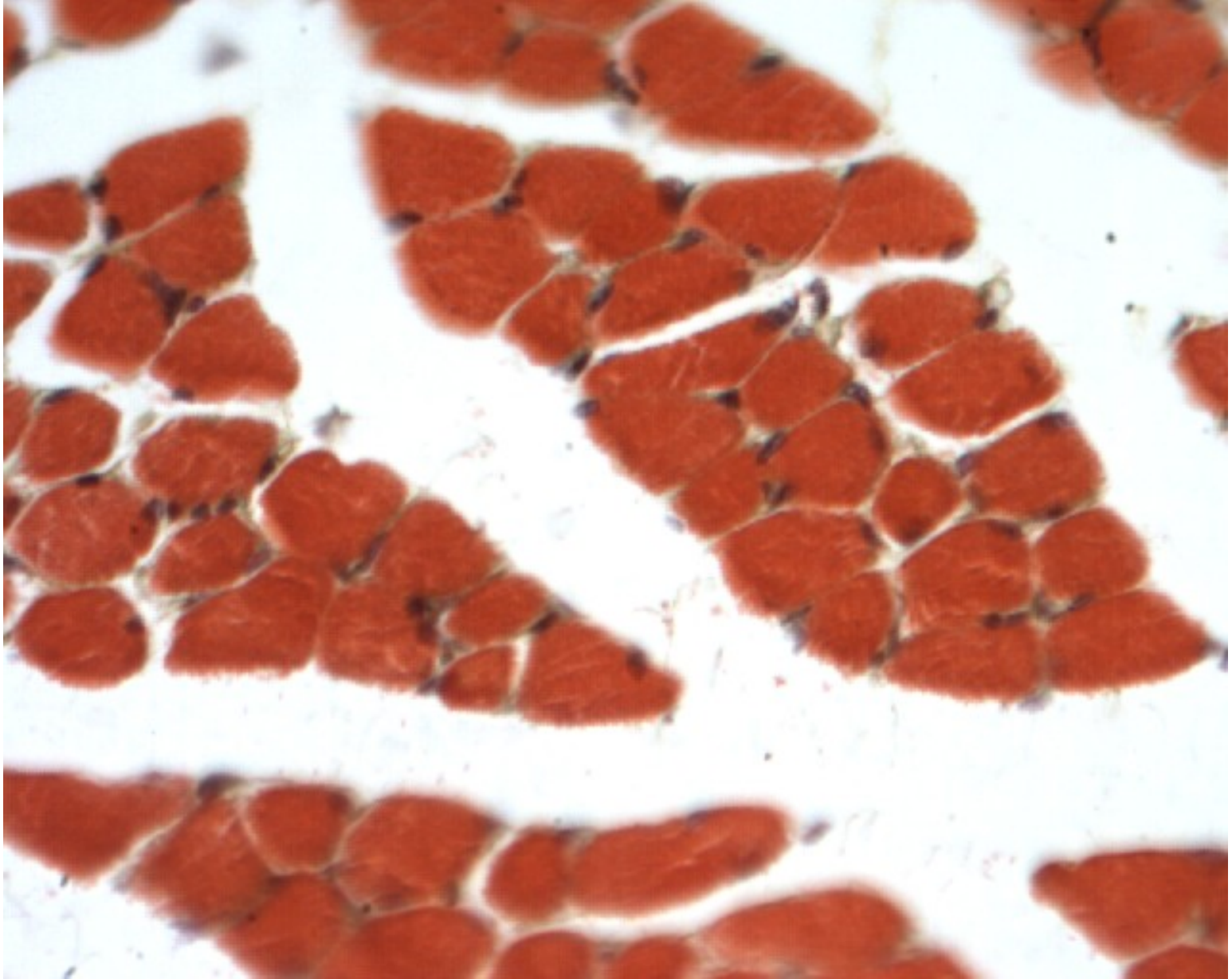
skeletal muscle



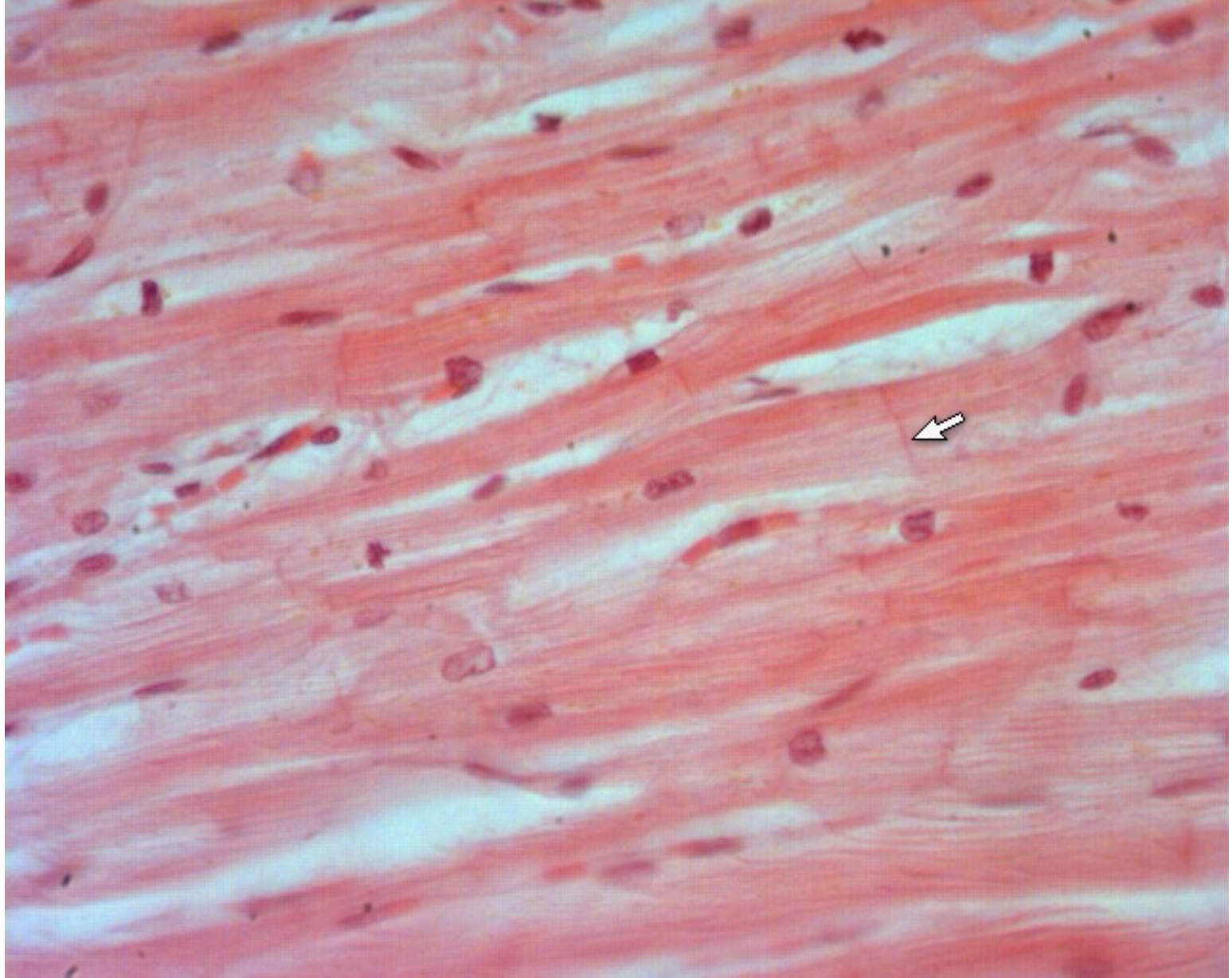
skeletal muscle



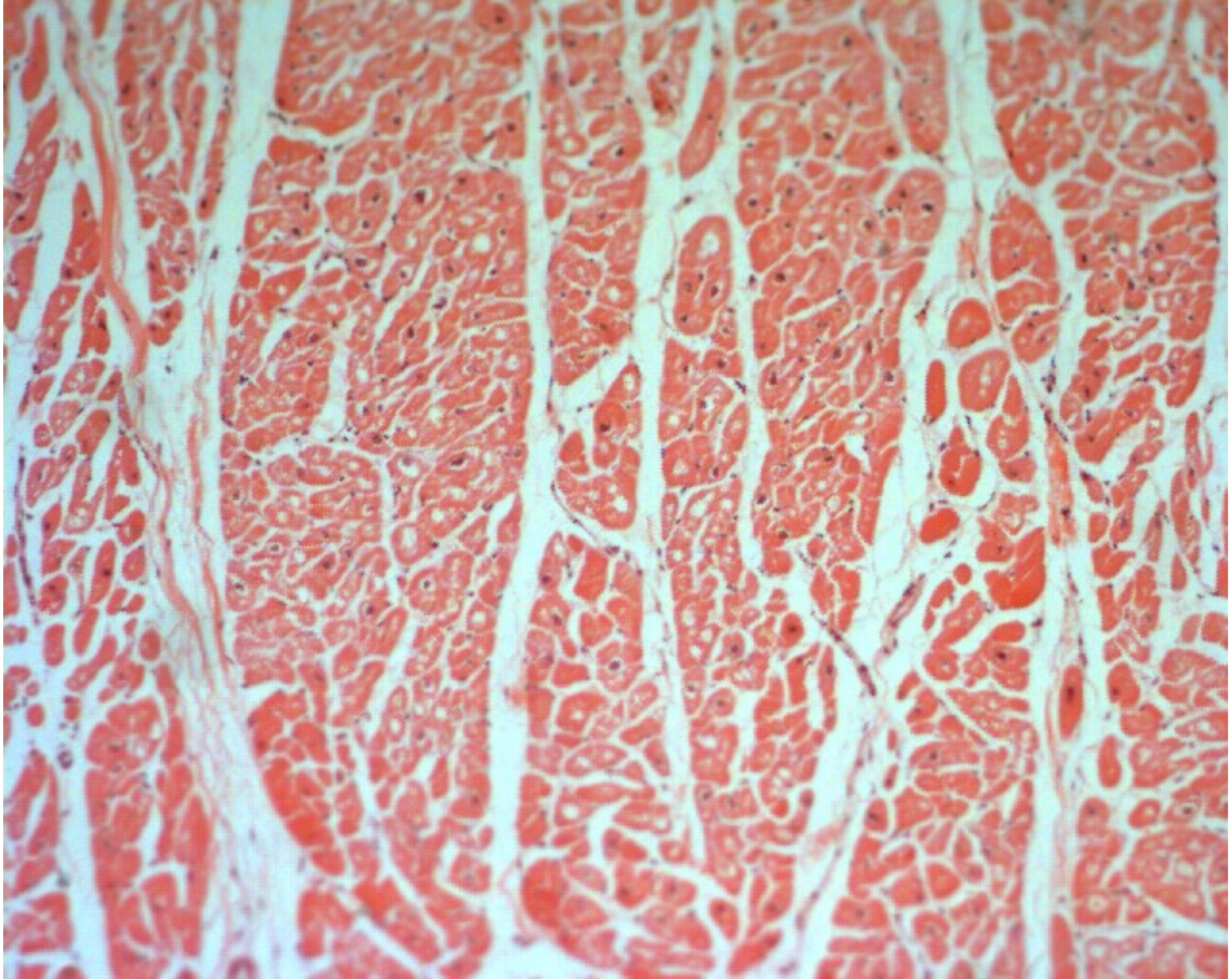skeletal muscle



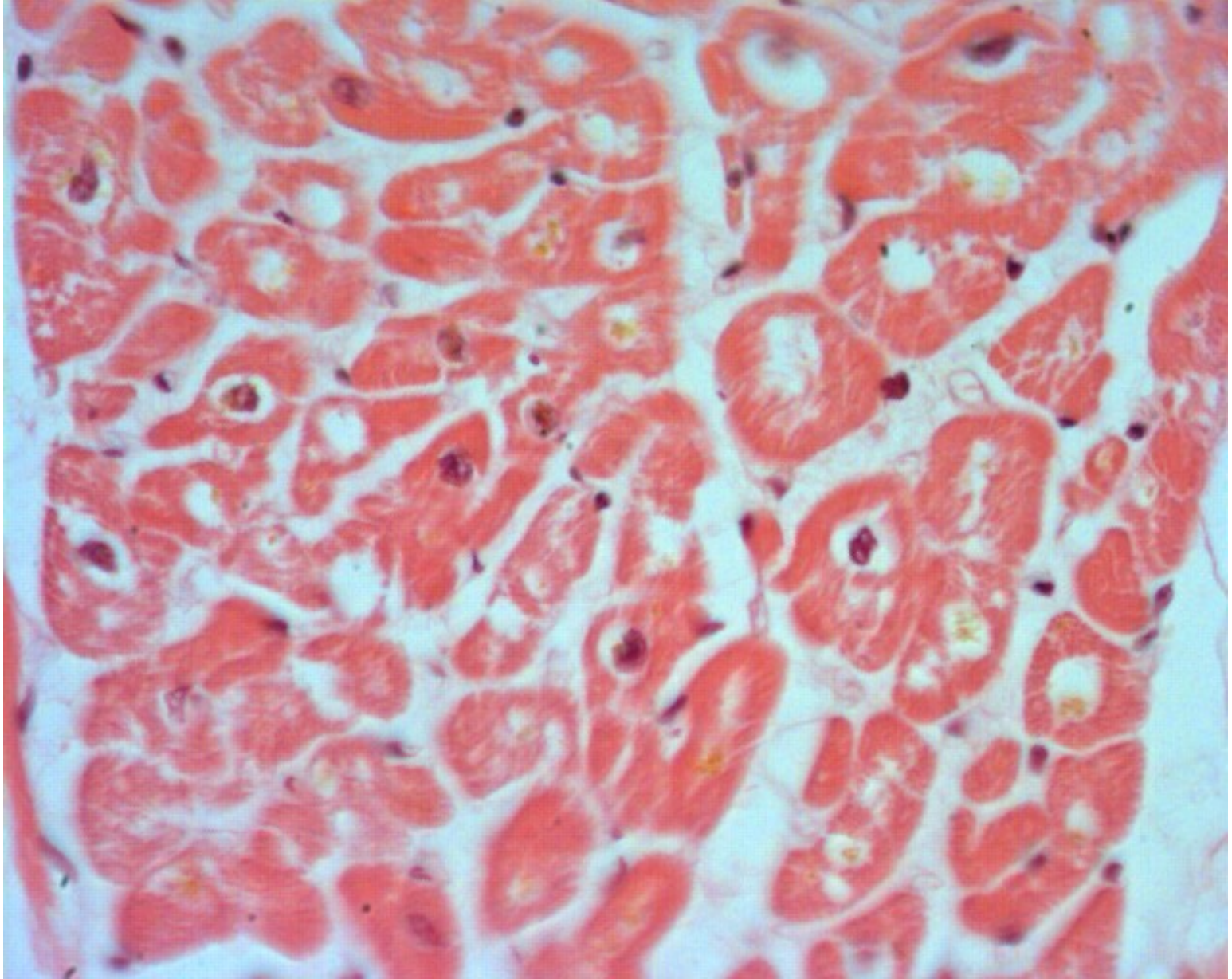
skeletal muscle



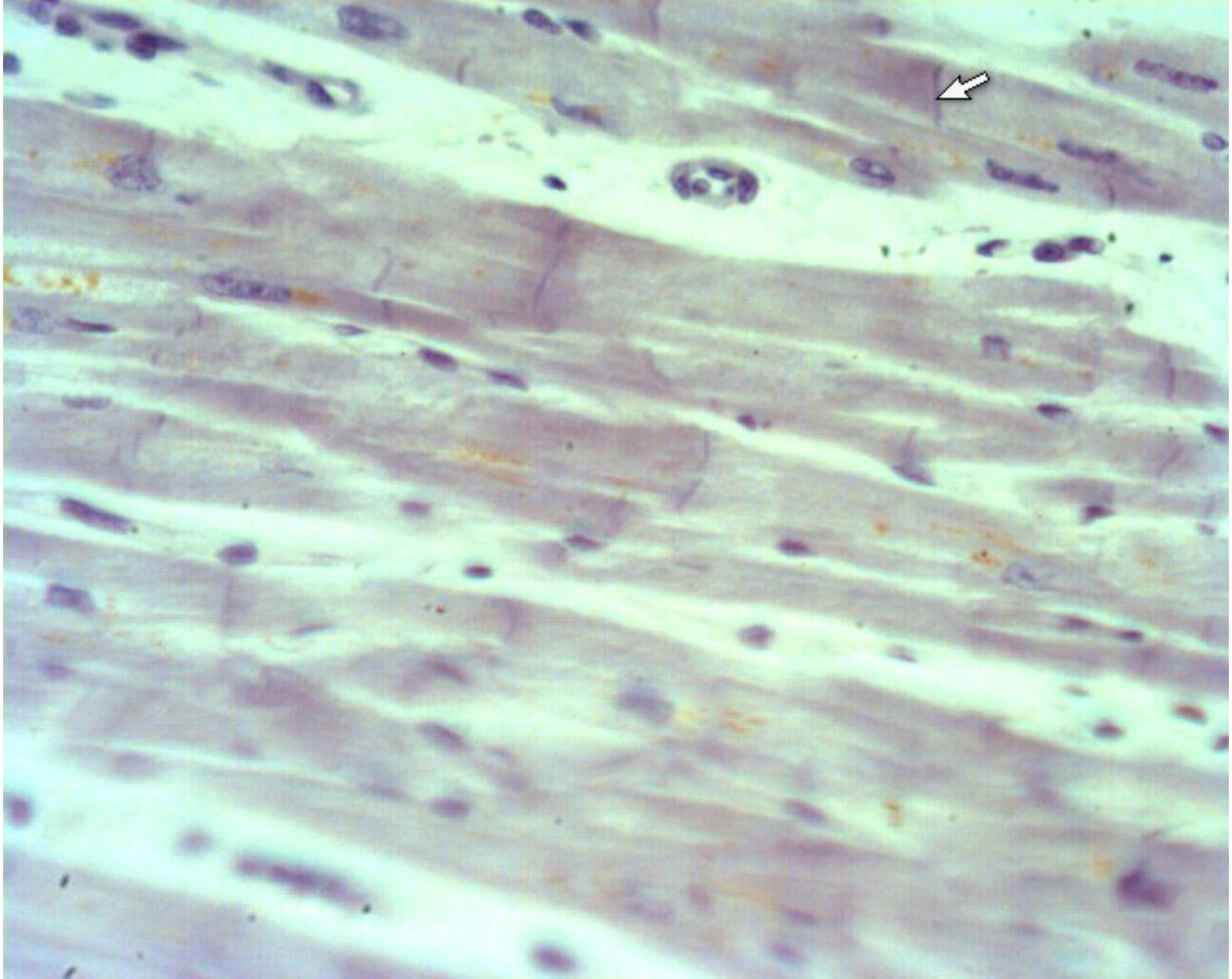
cardiac muscle



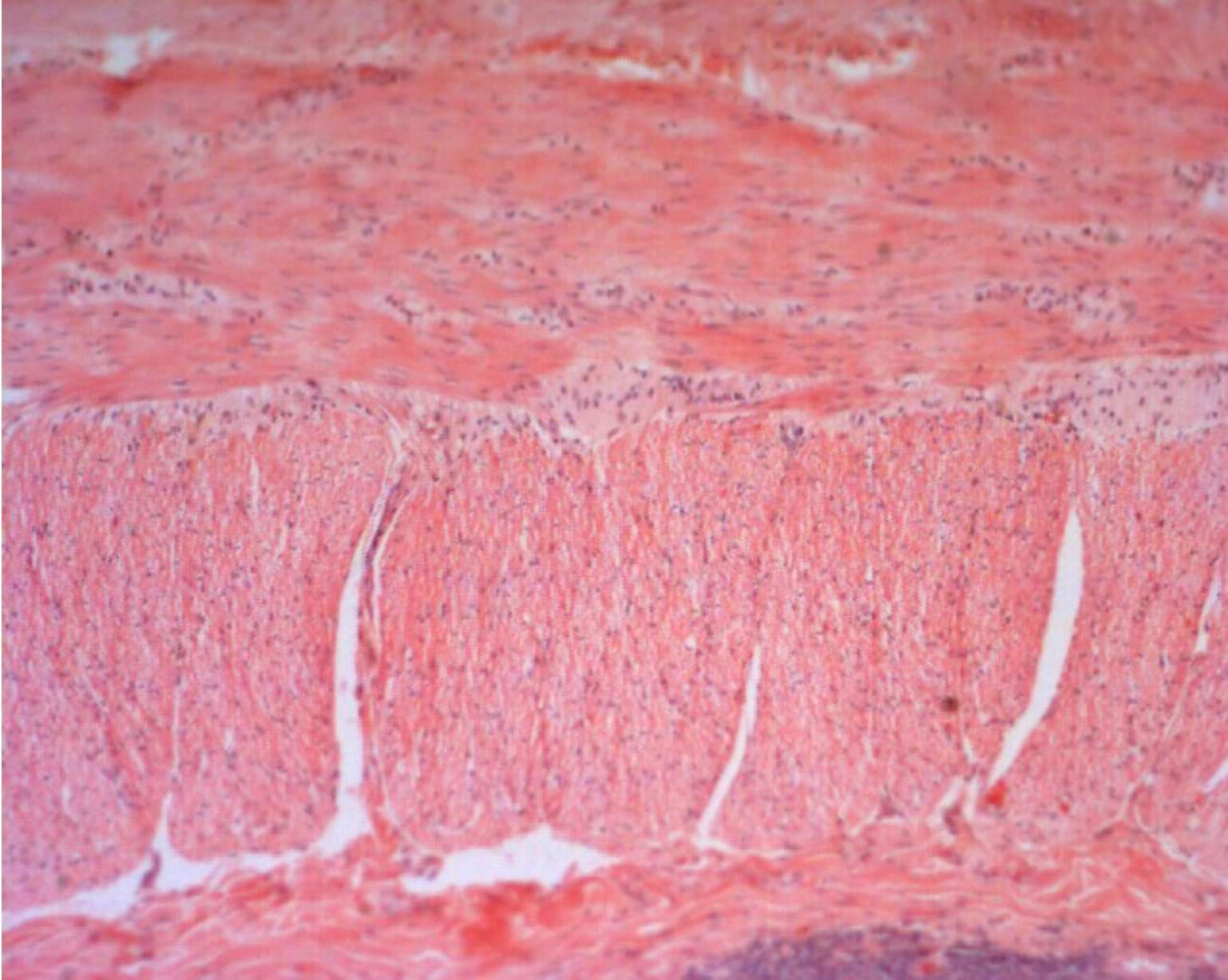
cardiac muscle



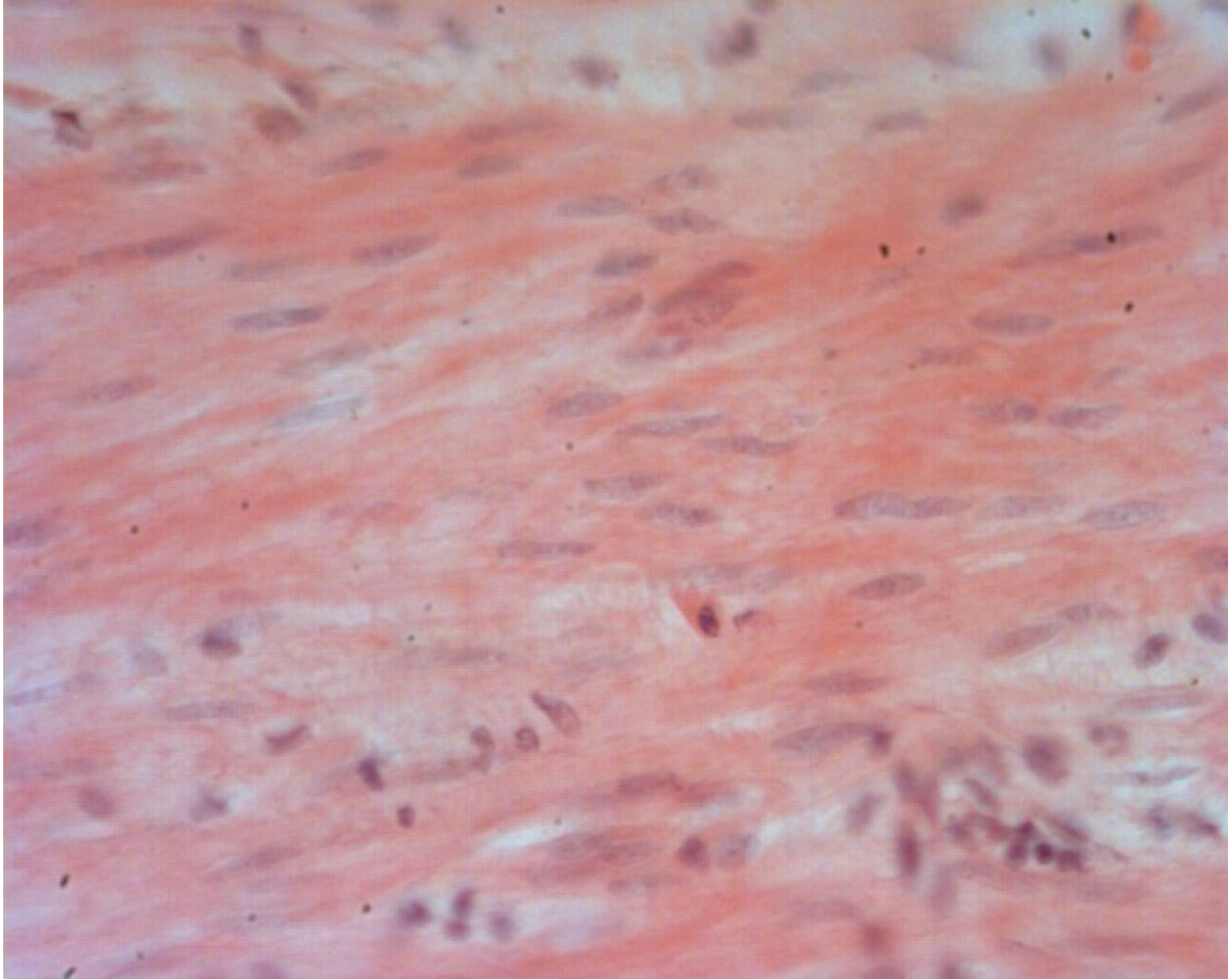
cardiac muscle



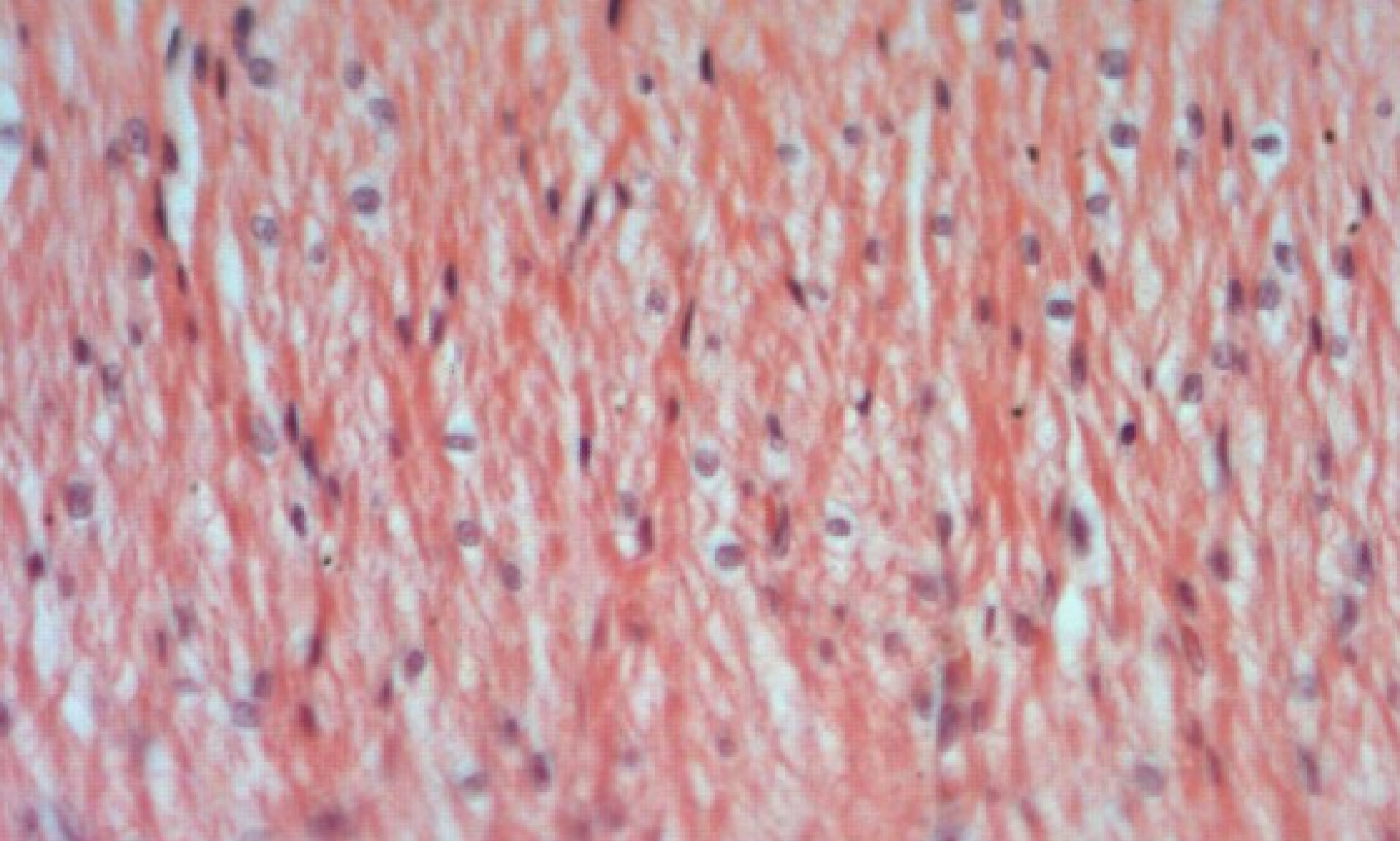
cardiac muscle and intercalated disc



smooth muscle



smooth muscle



smooth muscle